

Ankylos®

# Scientific Summary

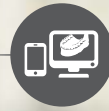

Comprehensive solutions for all phases of implant dentistry



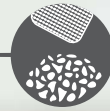
Professional and practice development

STEPPS™



Digital planning

Simplant®



Regenerative solutions

Symbios®



Implants

Ankylos®  
Astra Tech  
Implant System®  
Xive®



Restorations

Atlantis®



# Welcome

Are you looking for information about the outstanding results on tissue maintenance and long-term clinical results when using the Ankylos implant system? Or do you want to explore different prosthetic solutions and read about the importance of patient satisfaction? You will find the answers here, and much more.

This Scientific Summary provides a synopsis of the published key research findings supporting the Ankylos implant system. Each summary is based on facts retrieved from the original research article.

The Scientific Summary focuses on the following topics:

Tissue maintenance .....	9
Prosthetics and patient satisfaction .....	15
Long-term clinical results .....	23
References .....	28

Summary by Dentsply Sirona Implants of facts retrieved from the original articles.

For a more comprehensive view of the documentation and research on our products, please refer to our Scientific Reviews. The Scientific Reviews are available for download at [www.dentsplyimplants.com/science](http://www.dentsplyimplants.com/science)

To improve readability for our customers, Dentsply Sirona does not use ® or ™ in body copy. However, Dentsply Sirona Implants does not waive any right to the trademark and nothing herein shall be interpreted to the contrary.

# More than 25 years - connected with you

The Ankylos implant system was designed in 1985, on the premise that an implant could act prosthetically like a stable natural tooth. In more than 25 years of clinical use, the Ankylos system has been recognized for hard and soft tissue maintenance and high-quality, long-term esthetics.

**2008**

Ankylos C/X, designed for use with both non-indexed (C) and indexed (X) prosthetic components, is launched.

**2005**

Ankylos is provided with the Friadent plus implant surface and a micro-rough implant shoulder.

**1993**

Ankylos is launched.

**2005**

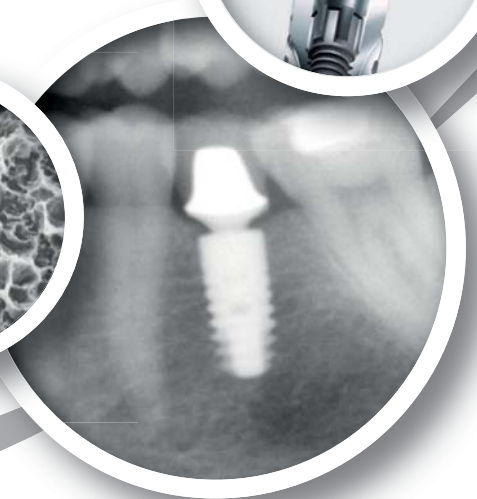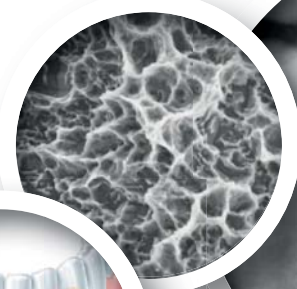
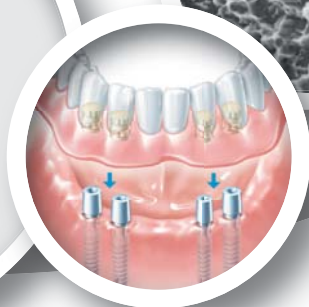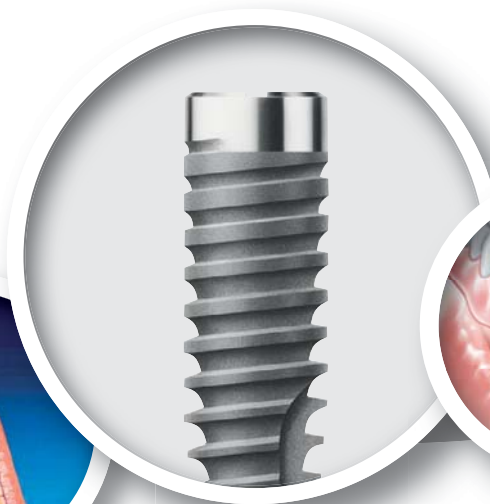
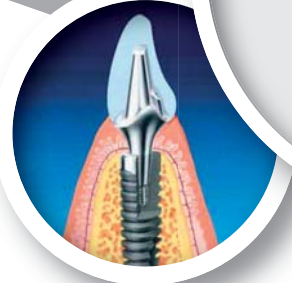The unique combination of tissue-stabilizing features of Ankylos is summed up under the name "Ankylos TissueCare Concept".

**2001**

The unique Ankylos SynCone concept for prosthetic overdentures was introduced.

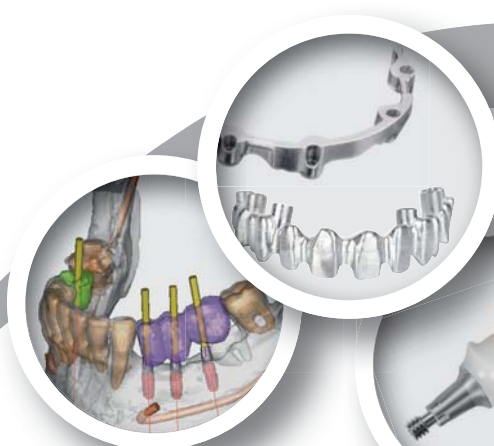
**1987**

The innovative implant system with its ground-breaking features, including tapered connection, significant horizontal offset and progressive thread design, is put to clinical use.



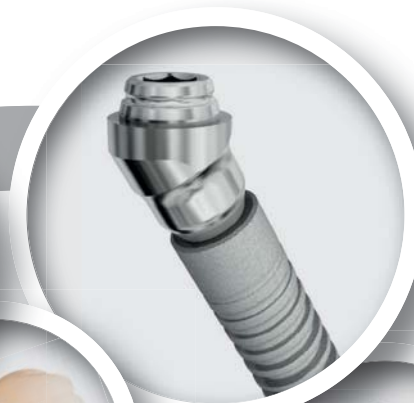## 2009

Going CAD/CAM - implant suprastructures are introduced for Ankylos.



## 2012

Introduction of the SmartFix Concept - the prosthetic solution for full arch restorations on implants placed at an angle.



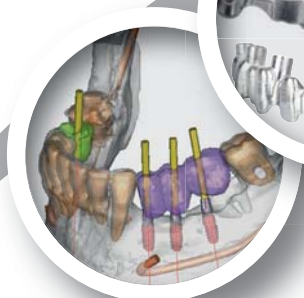
## 2013

Launch of Ankylos 6.6 mm. May minimize the need for vertical bone augmentation procedures.



## 2009

The Ankylos portfolio is further extended with computer-guided surgery capabilities, based on the market-leading Simplant software.



## 2011

TitaniumBase- two-piece CAD-CAM abutments.



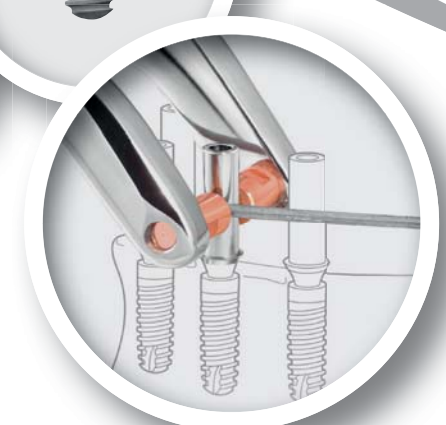
## 2012

Atlantis patient-specific CAD-CAM abutments.



## 2014

The worldwide unique WeldOne concept is launched by facilitating stable and durable chairside solutions.





## Clinical documentation on Ankylos<sup>®</sup> Implant System

The Ankylos implant system has several key features, including the friction-locked conical implant-abutment connection, the system-immanent horizontal offset, and the microstructured surface on the implant shoulder. The system has been used in various clinical indications for over 25 years.

Published data shows that placement of Ankylos implants is a safe and predictable treatment in both jaws for indications such as: single-tooth restorations, fixed partial/full prostheses, and overdentures. Moreover, there are published clinical results for implants immediately placed in extraction sockets, in grafted sites, and when using a one-stage surgical procedure followed by immediate loading.

Clinical studies with a follow-up between 1 and 8 years report that the Ankylos implants are safe to use rendering high implant survival rates, ranging from 94 to 100%. Support for clinical safety is further

confirmed in a retrospective study including more than 12,500 Ankylos implants with up to 20 years of documented clinical follow-up.

Good primary stability has been documented for Ankylos implants in several studies. Mean insertion torque values ranging from 28.8 to 47.5 Ncm have been reported, even for the Ø3.5 mm implant. Additionally, high patient satisfaction is reported.

Published, clinical studies report on the mean marginal bone level change around Ankylos implants after 1 year (range 0.01 to -1.32 mm), 2 years (range +0.21 to -0.78 mm) and 3 years in function (-0.6 mm).

For a complete list of references supporting the Scientific Review "Clinical documentation on Ankylos implant system", please refer to [www.dentsplyimplants.com/science](http://www.dentsplyimplants.com/science)

# The Ankylos<sup>®</sup> TissueCare Concept

Scientifically and clinically proven for maintaining hard and soft tissue over time, the Ankylos TissueCare Concept is the combination of unique features of the Ankylos implant system.

## SoftTissue Chamber™

The TissueCare connection and the micro-rough implant shoulder allow for subcrestal placement. In combination with a horizontal offset and the concave abutment design, a chamber for soft tissue and bone is created, supporting tissue stability.

## One-fits-all TissueCare connection

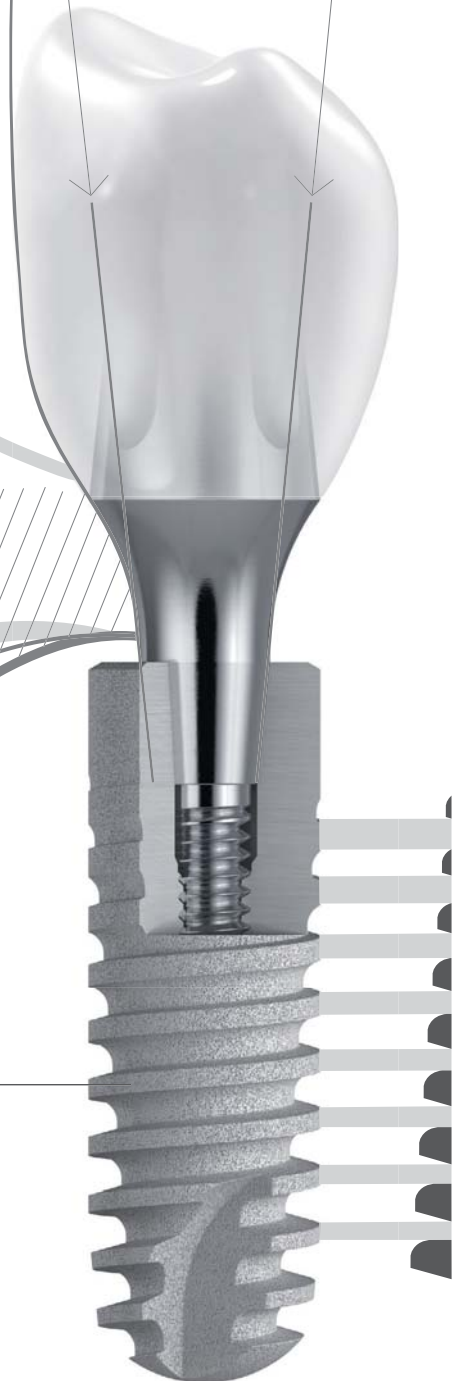All abutment sizes share one tapered connection simplifying the treatment protocol. A steep connection taper promotes friction lock without micro-movement, providing non-indexed prosthetics while offering an indexed option.

## Progressive Thread

The thread design transfers the functional load to the apical part of the implant and creates primary stability allowing for immediate loading.

## Friident<sup>®</sup> plus surface

The grit-blasted and high temperature-etched Friident plus microstructure excels by rapid bone formation on the implant surface. This results in early osseointegration and high bone-to-implant contact.





# Tissue maintenance

The Ankylos implant system has several unique key features, including the friction-locked conical implant-abutment connection, the system-immanent horizontal offset, and the microstructured surface on the implant shoulder. Together, these features provide the basis for predictable tissue maintenance. In this section, we present the excellent results on hard and soft tissue maintenance around the Ankylos implant system.

Summarized articles:

Immediate loading of single-tooth implants in the posterior region .....	10
Crestal bone changes around implants with reduced abutment diameter placed non-submerged and at subcrestal positions: a 1-year radiographic evaluation .....	11
Cone beam computed tomographic evaluation of implants with platform-switched Morse taper connection with the implant-abutment interface at different levels in relation to the alveolar crest .....	12
Immediate versus delayed functional loading of implants in the posterior mandible: a 2-year prospective clinical study of 12 consecutive cases .....	13

# Immediate loading of single-tooth implants in the posterior region

**Authors:** Abboud M, Koeck B, Stark H, et al.

**Published in:** Int J Oral Maxillofac Implants 2005;20(1):61-8.

## Aim

To evaluate the clinical outcome of single implants placed in the posterior maxilla and mandible applying an immediate loading protocol.

## Material and Methods

In this prospective clinical study patients in need of single implant treatment in the posterior region were included.

20 patients were rehabilitated with Ankylos implants (Dentsply Sirona Implants), where a standard solid abutment and a temporary crown were placed at the same visit.

During the following 5 weeks, several re-call visits were scheduled to follow-up on soft tissue healing, make the final impression and for monitoring implant stability. The provisional crown was modified in order to guide the soft tissue healing to achieve better esthetics. Following 6 weeks of healing the provisional crown was removed and after impression taking a permanent crown was cemented.

Periapical radiographs were taken at day of surgery (baseline) and after 3, 6 and 12 months to record changes in the peri-implant hard tissues. The bone levels were evaluated by measuring the distance from the implant reference point (mesial and distal aspects of the implant shoulder) to the most coronal implant-bone contact point. Other clinical parameters registered were papilla height, occurrence of inflammation and Periotest values.

## Results

In total 20 patients received 20 immediately loaded implants, of which 11 implants were installed in molar sites and 9 in premolar positions.

One implant failed during the 12 month study period and another implant was associated with peri-implantitis due to temporary cement excess. The peri-implantitis was successfully treated.

From implant placement to the 1-year follow-up the marginal bone level was well maintained with a mean marginal bone level change of 0.01 mm (Table 1).

Follow-up time	IP - 3 months	IP - 6 months	IP - 1 year
Maxilla	-0.02	-0.06	0.00
Mandible	-0.02	-0.02	0.03
Total	-0.02	-0.04	0.01

Table 1. Mean marginal bone level changes from implant placement (IP) to 3, 6 and 12 months of follow-up.

After 180 and 360 days the mean Periotest value measured -4. Values < 0 indicate that osseointegration is achieved<sup>1</sup>, while values > 9 indicates lack of osseointegration.

All patients showed good soft tissue health confirmed by low frequencies of plaque occurrence and no inflammatory signs. A papilla height gain was seen in 16 patients after 1 year.

## Discussion and Conclusion

From this 1-year prospective study it was concluded that immediately loaded single implants placed in the posterior region is a predictable treatment with good hard and soft tissue responses. However, a careful patient selection, treatment planning and longer follow up with more patients is needed.

### Reference:

1. Schulte W, Lukas D. Periotest to monitor osseointegration and to check the occlusion in oral implantology. J Oral Implantol 1993;19:23-32.

# Crestal bone changes around implants with reduced abutment diameter placed non-submerged and at subcrestal positions: a 1-year radiographic evaluation

**Authors:** Donovan R, Fetner A, Koutouzis T. et al.

**Published in:** J Periodontol 2010;81(3):428-34.

## Aim

By means of a retrospective approach, the aim of this study was to evaluate the 1-year marginal bone level changes around non-submerged and subcrestally placed implants with reduced abutment diameters.

## Material and Methods

Fifty patients with 69 Ankylos implants (Dentsply Sirona Implants) from a private practice were included in this review. Surgical procedures were performed according to the manufacturers' instructions with special attention to place the platform of the implant 1 to 2 mm subcrestal to the buccal bone. Immediate temporarization followed and the osseous void coronal to the platform was grafted (PegGen P15, Dentsply Sirona Implants) before the flaps were sutured. Permanent single crown restorations were delivered 3 to 4 months after implant surgery.

Intra-oral periapical radiographs were taken at implant surgery, at crown delivery and at last follow-up visit, where the mean follow-up was 14 months (range 9-20 months). The depth of the subcrestal position was measured at mesial and distal sites, both at implant placement and at subsequent follow-up visits. The level of mesial and distal bone-to implant contact was also recorded and bone level changes were calculated.

Descriptive statistics were calculated and comparison between mesial and distal sites, and changes over time were calculated using t test and two-sample t test, respectively.

## Results

All 69 implants remained osseointegrated but due to poor radiographic quality only 131 of totally 138 sites were included in the statistical analysis. In mean, mesial

and distal sites were placed 1.37 mm and 1.28 mm subcrestally at surgery. There was no statistical significant difference in loss of marginal bone between mesial and distal sites or between sites in the maxilla versus the mandible. Overall mean bone remodeling was 0.11 mm. Frequency analysis of implants losing more than 0.5 mm was 14% in the maxilla and 6% in the mandible.

Furthermore, there was no correlation between the level of subcrestal placement and loss of marginal bone. Subcrestal implant position had a significant correlation with hard tissue deposition on the implant shoulder at the last follow-up visit.

Subgroup	n	Bone remodeling (mm ± SD)
Mesial	68	-0.09 ± 0.26
Distal	63	-0.12 ± 0.35
Maxilla	95	-0.12 ± 0.33
Mandible	36	-0.05 ± 0.21

Table 1. Mean marginal bone remodeling for different subgroups in the study.

## Discussion and Conclusion

Minimal loss of marginal bone was reported around the Ankylos implants when placed 1-2 mm under the buccal marginal bone crest and loaded immediately. The result is in part due to the reduced abutment diameter, a concept called "platform switch", which enables a greater area for biological width formation and the establishing of bone at or over the implant platform.

# Cone beam computed tomographic evaluation of implants with platform-switched Morse taper connection with the implant-abutment interface at different levels in relation to the alveolar crest

**Authors:** Koutouzis T, Neiva R, Nair M. et al.

**Published in:** Int J Oral Maxillofac Implants 2014;29(5):1157-63.

## Aim

To evaluate, by means of CBCT, the buccal and lingual bone level changes around Ankylos CX implants when placed at different depths in relation to the buccal bone crest.

## Material and Methods

A prospective study design was undertaken. Patients in need of single implant rehabilitation were consecutively included in the study. Implants were placed at 3 different levels in relation to the buccal bone crest; equicrestal (Group 0), 1 mm subcrestal (Group 1) or 2 mm subcrestal (Group 2). After osteotomy preparation, the buccal bone thickness was measured. Ten patients were randomized to each group and each patient received 1 Ankylos CX implant (Dentsply Sirona Implants). After implant placement Ankylos Standard/C abutments were then immediately connected and a temporary crown (Dentsply Sirona Implants) was placed. Four months later a permanent crown was screwed into place.

CBCT evaluation took place at 12 months after implant placement. A centric section of each implant (a median section) was used for conducting the analyses according to the main variables presented in Table 1.

Descriptive statistics were calculated. Statistical tests were performed to evaluate differences between the groups with regards to the different variables measured and the level of significance was set to  $p < 0.05$ .

## Results

At 1 year the mean crestal implant positions were for group 0 = -0.04 mm, group 1 = 0.34 mm and for group 2 = 1.33 mm. It was found that the vertical change in buccal bone was smallest in group 0 followed by group 1 and group 2, respectively. The marginal bone height was minimally reduced in group 0 (-0.04 mm) and maintained in both group 1 and 2 (e.g. existing bone-to-implant contact at or above the platform). For the buccal/lingual sites, the bone was located at the platform in all groups, however, coronal to the platform in 0%, 40% and 75% in group 0, 1 and 2, respectively. Thin buccal wall thickness was correlated to more buccal bone remodeling in group 1 and 2.

## Discussion and Conclusions

The buccal and lingual crestal positions of the implant, evaluated by CBCT, followed the same pattern as when evaluated by conventional radiographs<sup>1</sup>. The position of the implant abutment interface in relation to the buccal bone crest is decisive for the amount of bone remodeling to occur.

## Reference:

1. Koutouzis T, Neiva R, Nonhoff J, Lundgren T. Placement of implants with platform-switched Morse taper connections with the implant-abutment interface at different levels in relation to the alveolar crest: a short-term (1-year) randomized prospective controlled clinical trial. Int J Oral Maxillofac Implants 2013;28(6):1553-63.

CBCT variables	Definition
Crestal implant position	The distance from the bone crest (buccal/lingual) to the implant platform
Marginal bone height	The distance between the implant platform and the (buccal/lingual) first visible bone-to-implant contact
Bone crest location in relation to the implant platform	The bone coronal to, at, or apical to the implant platform (i.e. above the implant-abutment junction, Yes/No)

Table 1. Definitions for the CBCT variables used in the study.

# Immediate versus delayed functional loading of implants in the posterior mandible: a 2-year prospective clinical study of 12 consecutive cases

**Authors:** Romanos GE, Nentwig GH.

**Published in:** Int J Periodontics Restorative Dent 2006;26(5):459-69.

## Aim

This randomized clinical study aimed to investigate the clinical performance of Ankylos implants subjected to either immediate or delayed loading when placed in the posterior mandible.

## Material and Methods

Twelve patients being bilaterally edentulous in the posterior mandible were included in the investigation. In a randomized manner, one side received 3 Ankylos implants (Dentsply Sirona Implants) which were subjected to submerged healing for 3 months. Following 2-stage surgery Sulcus Formers (Dentsply Sirona Implants) were placed and replaced the following week by straight or angulated standard healing abutments after which loading with splinted, cemented, temporary crowns took place.

On the same day as the submerged healing group received their provisional restorations, 3 additional Ankylos implants were placed in the contralateral side applying 1-stage surgery and an immediate loading protocol using provisional, splinted crowns. Occlusal contact only occurred during maximal intercuspation. Following 2 weeks of loading the provisional restorations were removed to allow for impression taking with special Ankylos transfer caps (Dentsply Sirona Implants). Definite prostheses were later cemented 6 weeks from the time of immediate loading.

During the investigation period both panoramic radiographs and clinical recordings were made. Plaque index, sulcus bleeding index, probing pocket depth, width of the keratinized mucosa as well as mobility values were recorded at 3, 6, 9, 12, 18 and 24 months after loading.

## Results

During the mean loading period of 25.3 months, no complications or postoperative infections were recorded. No statistical differences could be found

between Ankylos implants subjected to either delayed or immediate loading with respect to any of the clinical recordings made, see Table 1.

Bone loss never exceeded 2 mm around any implant during the observation period and 29 implant sites showed no bone loss.

## Discussion and Conclusion

The Ankylos Implant System has features with progressive thread design and a large total surface area for increased mechanical stability which allows for successful replacement of molar teeth with only one implant, as seen in the current study irrespective of loading protocol. Although there was no statistical significance between the two treatment groups in this study, with respect to clinical and radiological parameters used, does not mean that the conditions are the same for the two groups. The sample size was small in this investigation, thus studies of immediate loading in a larger patient population with longer follow-up periods are needed.

Clinical Parameter	Time for follow-up			
	Permanent prosthesis		24 months of loading	
	Delayed loading	Immediate loading	Delayed loading	Immediate loading
Plaque Index	0.4	0.3	0.8	0.4
Sulcus Bleeding Index	0.3	0.3	0.3	0.5
Probing Pocket Depth	1.8 mm	1.6 mm	2.1 mm	1.9 mm
Width of keratinized mucosa	3.7 mm	2.6 mm	3.3 mm	2.5 mm

Table 1. Clinical parameters evaluated.



# Prosthetics and patient satisfaction

Patient satisfaction and patient quality of life have become important factors when evaluating success of implant therapy today. In this section, we present results on patient satisfaction when using the Ankylos implant system. Moreover, clinical results when using different prosthetic solutions, such as the friction-locked connection with SynCone abutments, are presented here.

Summarized articles:

Prospective study with a 2-year follow-up on immediate implant loading in the edentulous mandible with a definitive restoration using intra-oral welding .....	16
Immediate rehabilitation of the edentulous mandible using Ankylos SynCone telescopic copings and intraoral welding: a pilot study .....	17
Functional and esthetic considerations for single-tooth Ankylos implant-crowns: 8 years of clinical performance .....	18
Immediate loading of dental implants in the edentulous maxilla .....	19
AICRG, part IV: patient satisfaction reported for Ankylos implant prostheses .....	20
Implant-supporting telescopic maxillary prostheses and immediate loading .....	21

# Prospective study with a 2-year follow-up on immediate implant loading in the edentulous mandible with a definitive restoration using intra-oral welding

**Authors:** Degidi M, Nardi D, Piattelli A.

**Published in:** Clin Oral Implants Res 2010;21(4):379-85.

## Aim

The purpose with this investigation was to evaluate whether intra-oral welding is a viable concept for fabrication of restorations to be used for immediate rehabilitation of the edentulous mandible in combination with Ankylos implants.

## Material and Methods

All 20 included patients were completely edentulous in the mandible. Following full-thickness flap surgery, they all received 4 Ankylos implants (Dentsply Sirona Implants) placed in the intraforaminal region. The implants were placed subcrestally (1.5–2 mm below the crest) in healed sites. If sufficient primary stability was reached (see Table 1), implants were immediately connected to Balance Base abutments (Dentsply Sirona Implants) through screw retention.

	Insertion torque (Ncm)	Implant stability quotient (ISQ)
Minimum value for patient inclusion	≥25	≥60
Mean insertion value	42.5	81.9

Table 1. Primary stability.

A retention cap made from titanium was placed on top of each Balance Base abutment after which a 2-mm-diameter titanium bar was intraorally welded to the most distal abutment. Using pliers, the bar was then shaped to make gentle contact with the abutment situated next to the one just welded. This procedure was then repeated for all abutments. Special care and firm pressure was applied to ensure complete contact between the bar and abutment during the

welding procedure to secure a perfect joint between the parts. The electrical current applied through the copper electrodes increased the core temperature of the titanium bar to around 1660°C. The process last for 2-5 ms and the copper electrodes dissipate the generated heat, thus no heat is transferred to the surrounding tissues causing no distress to the patient.

Once passive fit of the framework has been confirmed through the Sheffield 1 screw test, the soft tissue is repositioned around the abutments and the framework is sandblasted and opaques. The prosthetic framework was relined with acrylic and checked for correct vertical length, then removed from the oral cavity and completely filled with acrylic and reconnected to the abutments on the same day of surgery.

During the 2-year observation period recordings of implant survival, periimplant bone level changes, level of marginal gingiva as well as biological and technical complications were made.

## Results

No implant failures were recorded during the study and following 2-years from implant treatment the mean marginal bone growth was 0.21 mm with mean pocket probing depth measuring 1.38 mm. No biological or technical complications were recorded.

## Discussion and Conclusion

No adverse effect from the intra-oral welding technique on implant survival or marginal bone loss was observed. It was shown that it is possible to successfully rehabilitate the edentulous mandible by immediate loading of Ankylos implants when using an intraorally welded prosthetic framework.

# Immediate rehabilitation of the edentulous mandible using Ankylos SynCone telescopic copings and intraoral welding: a pilot study

**Author:** Degidi M, Nardi D, Sighinolfi G, et al.

**Published in:** Int J Periodontics Restorative Dent 2012;32(6):e189-94.

## Aim

The objective with this prospective investigation was to test whether SynCone abutments in combination with an intraoral welding technique is a viable concept for rehabilitating edentulous patients with immediately loaded Ankylos implants.

## Material and Methods

Patients recruited for the study all had a complete edentulous mandible. They were rehabilitated with four Ø3.5 mm Ankylos implants (Dentsply Sirona Implants), all placed in the interforaminal region in healed sites. Insertion torque and implant stability quotient (ISQ) were monitored during implant insertion and if the insertion torque or the ISQ value did not reach 25 Ncm or 60 respectively, the patients were excluded from the study.

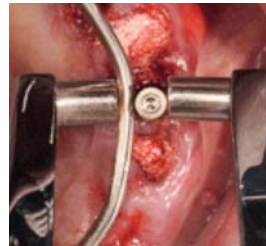A full-thickness flap was elevated to allow for implant placement following connection of the definitive SynCone 5-degree abutments. Special care for parallel placement was taken. Conical caps (Dentsply Sirona Implants) made out of titanium were firmly engaged on top of the abutments and welded to a grade 2 titanium bar (Ø2 mm) utilizing the intraoral welding technique.

To create further support for teeth the prosthetic framework was removed and titanium bars were welded onto the framework extraorally. Once completed, passive fit for the complete construct was confirmed followed by sandblasting and opaquing. Soft tissue was repositioned around the abutments. The prosthesis was delivered to the patient on the same day.

The patients were regularly followed for 12 months post implant placement, registering technical and biological complications, implant survival, restoration success or any adverse events.

## Results

A total of 24 patients were included in the study, of these 2 patients were excluded due to insufficient insertion torque or ISQ. For the included patients the mean insertion torque and ISQ was 44.5 Ncm and 79.1



respectively. All implants but 1 remained in function at the 12-month follow-up appointment, rendering a survival rate of 98.9%. Due to this implant failure, 1 prosthesis needed repairing resulting in a prosthetic success of 95.5%. Composite

resin or acrylic resin structures showed no signs of chipping or fractures.

## Discussion and Conclusion

Although more long-term studies are needed to confirm the results from this study, it is shown that it is possible to immediately restore the edentulous mandible with a definitive prosthesis supported by Ankylos implants connected to SynCone 5-degree abutments and an intraorally welded titanium framework.

# Functional and esthetic considerations for single-tooth Ankylos implant-crowns: 8 years of clinical performance

Authors: Doring K, Eisenmann E, Stiller M.

Published in: J Oral Implantol 2004;30(3):198-209.

## Aim

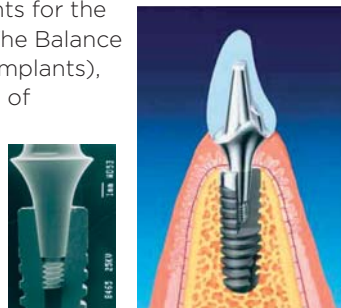
The objective of this study was to evaluate the clinical outcome of Ankylos implants when restored with single crowns in anterior and posterior regions.

## Material and Methods

275 Ankylos implants (Dentsply Sirona Implants) for single-tooth replacement were monitored for a period of up to 8 years.

The implants were placed slightly below the crestal bone level, to allow for an optimal emergence profile. During the healing period different sizes of sulcus formers were used to shape the peri-implant soft tissue and, if needed, they were replaced several times to form natural contours of the soft tissue.

Following the healing period and stabilization of the soft tissue the final abutments were selected based on the anatomic requirements for the final crown restoration. The Balance abutments (DENTSPLY Implants), of which 264 were made of titanium and 11 out of ceramics, were customized so that the final crown provided a natural, esthetic solution for each clinical case. The final restorations, either metal-ceramic or all-ceramic crowns, were formed on the customized abutments to maximize esthetical appearance and function.



The Balance abutments were connected using a customized transfer index, with a torque of 15 Ncm and the final crowns were all cemented using a glass ionomer cement.

## Results

Only 5 implants were lost during the healing phase, rendering a survival rate of 98.2%. The mean observation period was 3.2 years with no further implant losses. There were no technical complications associated with the prosthetic components. The soft tissues were stable with a slight increase in papilla height over time. One year after loading, radiographs showed the crestal bone to be at or above the level of the implant shoulder in 50% of the cases. Patients rated the esthetical appearance and comfort of the single-implant restorations in a range from "good" to "excellent".

## Discussion and conclusion

Single-tooth replacement with Ankylos implants resulted in stable hard- and soft tissues, good esthetics and function. Technical and biological complications were not observed with the Ankylos implant system in the current study. Complications that have been described in the literature with other implant systems, i.e. screw loosening, screw breaking or crown breaking, seem to be absent when using Ankylos implants and it suggests a functional safety of the tapered connection between implant and abutment.

# Immediate loading of dental implants in the edentulous maxilla

Authors: Eccellente T, Piombino M, Piattelli A, et al.  
Published in: Quintessence Int 2011;42(4):281-9.

## Aim

This study aimed to evaluate Ankylos implants placed in the edentulous maxilla and immediately loaded with removable prostheses supported by SynCone abutments.

## Material and Methods

Patients recruited for the study all needed a total rehabilitation of the maxilla. Forty-five patients received four Ankylos implants (Dentsply Sirona Implants), placed either in extraction sockets or in healed ridges. All implants were placed 1 mm subcrestally and autogenous bone graft was used when deemed necessary by the surgeon. SynCone abutments (Dentsply Sirona Implants) were connected to the implants and prefabricated copings were polymerized into the existing denture base directly in the mouth. Patients were instructed in oral and denture hygiene procedures and were recommended soft diet for the initial healing period. After a healing period of 6 months, 29 patients received a new denture, and 11 SynCone abutments needed to be replaced before connecting a new denture.

Panoramic radiographs were taken after 6 months and then yearly thereafter. Other parameters registered were; modified sulcus bleeding index, modified plaque index, patient satisfaction and any technical complications.

## Results

In total 45 patients received 180 Ankylos implants. Two implants were removed during the first 3 months due to lack of osseointegration, one implant fractured after 6 months in function, and one additional implant was lost due to peri-implantitis at 19 months, resulting in an overall implant survival rate of 97.8% after an average observation period of 26.7 months (range 12 to 54 months). The prosthesis survival rate was 100% and only a few minor technical complications (such as abutment loosening and denture fracture) occurred.

During the study period the bone levels were stable with bone in contact, close or above the implant-abutment connection, in 48.8% of the implant sites.

All patients showed good soft tissue health, confirmed by low values of both sulcus bleeding index and modified plaque index. No swelling or suppuration was observed.

The majority of the patients were satisfied with the phonetics, function, esthetics, retention of the restoration and the oral hygiene (Figure 1).

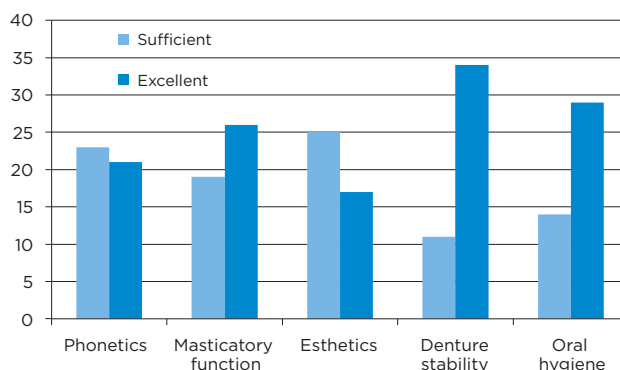


Figure 1. Patient satisfaction after 12 months.

## Discussion and Conclusion

The treatment with an immediately loaded removable prostheses supported by SynCone abutments is a reliable solution for the edentulous maxilla. The treatment modality resulted in a stable denture with very few prosthetic complications, a high patient satisfaction and good oral hygiene.

# AICRG, part IV: patient satisfaction reported for Ankylos implant prostheses

**Authors:** Morris HF, Ochi S, Rodriguez A, et al.  
**Published in:** J Oral Implantol 2004;30(3):152-61.

## Aim

The purpose was to study the degree of patient satisfaction from patients having replaced their natural teeth with implant supported prostheses.

## Material and Methods

The members of the AICRG (Ankylos Implant Clinical Research Group) consisting of more than 80 international clinicians (private and university settings), performed a patient survey after having rehabilitated the patients with implant supported prostheses (partial and complete restorations). This study included 478 patients who received 638 prostheses supported by more than 1500 Ankylos implants (Dentsply Sirona Implants) in both jaws. The Ankylos implant has a progressive thread design, a rough surface, a tapered abutment connection and a polished collar that does not have threads.

The patients had been followed for 3 to 5 years when the survey took place. There were 10 questions included in the survey.

## Results

A total of 95.6% of the patients reported that their chewing ability was good or even excellent after the treatment and 92% of the patients actually had an improvements in their chewing ability compared to the old prosthesis. The overall clinical function comparing new vs. old prosthesis was improved in 92.6 %, unchanged in 6.2% and decreased in 0.9% of the patients. Changes in their speech to the negative, was seldom experienced, 0.9%. The reported comfort

level when eating hot or cold food was high (96.3%) and most patients (98.8%) answered that there was no persistent pain or discomfort when using the prostheses.

Overall patient satisfaction	Yes (%)	No (%)
Do you like the new prosthesis	99.4	0.6
Would you repeat the treatment again if necessary	98.0	2.0
Would you recommend the treatment to a friend or relative	99.1	0.9
Did the advantages of the treatment outweigh any disadvantages that you may have identified	98.9	1.2

Table 1. Percentage of patients responding yes or no to the questions related to the overall patient satisfaction of the implant supported prosthetic treatment.

## Discussion and Conclusion

This study report patients' satisfaction from 478 patients treated worldwide with Ankylos implant supported prostheses at private settings and university clinics. Follow-up time was 3 to 5 years. In general satisfaction was very high. The patients responded that they would not hesitate to have the Ankylos-prostheses treatment repeated, would recommend the treatment to friends and relatives and felt that the advantages of the treatment was much greater than any disadvantages.

# Implant-supporting telescopic maxillary prostheses and immediate loading

**Authors:** Romanos GE, May S, May D.

**Published in:** Clin Implant Dent Relat Res 2014;16(3):412-8.

## Aim

In the present study the long-term clinical outcome is retrospectively evaluated for immediately loaded Ankylos implants when placed in the maxilla utilizing telescopic-retained removable prostheses.

## Material and Methods

A total of 26 patients with complete or partial edentulism in the maxilla were included in the study and rehabilitated with 117 Ankylos implants (Dentsply Sirona Implants). An immediate loading protocol was applied where implants were placed 1-3 mm subcrestally in both healed sites and extraction sockets. Conical pre-fabricated SynCone abutments (Dentsply Sirona Implants) were connected to all implants. Following flap closure, prefabricated copings were placed over the abutments and overdentures or partial dentures were relined chair-side and were to remain in place for 10 days.

Following 3 months in function, implant stability was evaluated. Peri-implant soft tissue health, prosthetic stability, complications, implant survival, implant success as well as bone level changes were evaluated over a minimum follow-up period of 2 years.

## Results

During the mean study period of 54 months, 7 implants failed rendering a survival rate of 94.0%.

There were no signs of hyperplastic gingival overgrowths, instead patients were presented with healthy peri-implant soft tissues.

Only 10 implants showed a mean bone reduction more than 2 mm and generally the crestal bone levels were stable during the follow-up period. Frequency analysis over crestal bone reduction per implant is shown in Table 1.

Patients were satisfied with their prostheses and there were no complications reported such as fractures or insufficient stability of the prosthesis.

Crestal bone reduction (mm)	Number of implants	% of implants
0	33	30%
1	44	40%
2	23	21%
3	10	9%
Total	110	100%

Table 1. Frequency analysis of peri-implant bone reduction at last follow-up.

## Discussion and Conclusion

Immediately loaded Ankylos implants in conjunction with telescopic implant-retained prosthesis in the maxilla poses as a viable treatment option for the edentulous maxilla with predictable long-term results and improved patient comfort and clinical outcome.



# Long-term clinical results

The Ankylos implant system has been in clinical use for more than 25 years. The long-term clinical documentation (i.e.  $\geq 5$  years) is one of the most important tools when showing evidence for that the Ankylos implant system is efficient, reliable and safe. In this section, excellent long-term results with  $\leq 20$  years of clinical follow-up are presented.

Summarized articles:

Double crown-retained maxillary overdentures: 5-year follow-up .....	24
Long-term evaluation of Ankylos dental implants, Part I: 20 year life table analysis of a longitudinal study of more than 12,500 implants .....	25
Treatment concept of the edentulous mandible with prefabricated telescopic abutments and immediate functional loading .....	26
Long-term results after subcrestal or crestal placement of delayed loaded implants .....	27

# Double crown-retained maxillary overdentures: 5-year follow-up

**Authors:** Frisch E, Ziebolz D, Ratka-Kruger P., et al.

**Published in:** Clin Implant Dent Relat Res 2015;17(1):22-31.

## Aim

The purpose of this study was to evaluate the survival rate of maxillary overdentures supported by 4 implants and retained by double crowns.

## Material and Methods

In a retrospective manner, 20 patients that were attending the maintenance program after being rehabilitated with 4 Ankylos implants (Dentsply Sirona Implants) were included. The implants were placed in the maxilla and retaining an overdenture using the Marbourg double crown (MDC) technique. The patients were treated in a private clinic between 1993 and 2011 and had all been followed for a minimum of 1 year. After submerged healing (3-4 months) prosthetic restoration followed. Primary telescopes were screw-retained to the implants. Secondary crowns were made within the denture, with a clearance fit and additional retention elements (TK Snap, Si-Tec GmbH, Herdecke, Germany). The overdentures were horseshoe-shaped, palatal-free, without transversal connectors.

After delivery of the final overdentures, radiographs, clinical assessments and maintenance program followed.

## Results

Twenty patients with 80 implants were studied. The average observational period was 5.6 years (range from 1 to 15 years) and the average age of the patient at implant placement was 63 years. One implant was lost, resulting in an implant survival rate of 98.75%. The overdenture housing the lost implant remained in function, rendering a prosthesis survival of 100%. Eight out of 20 patients had no technical

complications recorded and these patients were followed for in mean 6.5 years. Among the patients with technical interventions, the most common issues were telescopic crown screw loosening and fracture of denture teeth, see Table 1.

Peri-implant mucositis, defined as BoP, was evident at 38 implants (47.5%) in 15 patients (75%). Eight implants in 2 patients were classified as affected by peri-implantitis at the last visit (applying a definition of mean bone loss  $\geq 3.5$  mm, probing depth > 5 mm and BoP).

Type of technical issue	Number	Intervention/patient/year
Screw loosening (telescopic crown)	6	0.053
Attachment renewal	3	0.027
Loose abutment	2	0.018
Fracture of denture teeth or base, veneer repair and other	14	0.12
Overall occurrence	25	0.222

Table 1. List of technical complications reported during the 5-year follow-up.

## Discussion and Conclusion

This practice-based study followed 20 patients treated with double crown retained overdentures for in mean 5.6 years. The prosthesis survival rate is comparable to other retentive solutions followed for long time, although the number of patients was limited in this study.

# Long-term evaluation of Ankylos dental implants, Part I: 20 year life table analysis of a longitudinal study of more than 12,500 implants

**Author:** Krebs M, Schmenger K, Neumann K, et al.

**Published in:** Clin Implant Dent Relat Res 2015;17 Suppl 1:e275-86.

## Aim

The objective of this study was to evaluate the long-term clinical outcome of Ankylos implants.

## Material and Methods

Between 1991 and 2011, 36 oral surgeons treated 4206 patients with 12737 Ankylos implants (Dentsply Sirona Implants) for a variety of clinical indications (Table 1).

Indication	Number of implants (%)
Edentulous jaw	3042 (24)
Single tooth gap	2170 (17)
Partially edentulous patients	7394 (58)
Unknown	131 (1)

Table 1. Different indication groups.

Sixty percent of the implants were placed in patients aged between 51-70 years, 56% of the patients were women and 53% of the implants were placed in the maxilla. Range of implant length and diameter was 8-14 mm and 3.5-5.5 mm respectively. Patients were rehabilitated with 1 up to 19 implants.



Ankylos implant

Most implants (63%) were placed in normal bone quality, only 11% were placed in dense bone and 26% were placed in soft bone. To increase the primary stability of the implants placed in soft bone, a bone condensing procedure using bone spreaders was performed. The majority of implants (60%) was placed in conjunction with bone grafting or bone expanding procedures.

Clinical and radiographic evaluations were conducted at annual follow-ups.

## Results

On average the implants were followed for 60.7 months, with the longest follow-up being 240 months. In total 319 implant failures were recorded during the observational period, resulting in an overall implant survival rate of 97.5%. Most failures occurred within the first year from implant placement and before prosthetic loading. The main reasons for implant failures were failed osseointegration or peri-implant infection.

Following 17 years in function, a low rate of peri-implant bone loss was observed for those 125 implants that were analyzed. Less than 1 mm vertical bone loss was observed for 85.7% of the implants and soft tissue levels were maintained around 64% of the implants.

Follow-up	CSR (%)
1 year	98.2
5 years	97.3
12 years	95.2
15 years	94.5
17 years	93.3*

\*of the 12,737 implants included at the start of the study 125 implants were analyzed at the 17 year follow-up visit.

Table 2. Cumulative implant survival rate (CSR).

## Discussion and Conclusion

In conclusion, this study indicates good long-term clinical outcome with Ankylos implants with respect to implant survival and peri-implant bone levels for various clinical indications.

# Treatment concept of the edentulous mandible with prefabricated telescopic abutments and immediate functional loading

**Authors:** Romanos GE, May S, May D.

**Published in:** Int J Oral Maxillofac Implants 2011;26(3):593-7.

## Aim

This retrospective study aimed to evaluate long-term clinical results of Ankylos implants when connected to prefabricated telescopic abutments and overdentures immediately after surgery.

## Material and Methods

Included patients all had received Ankylos implants (Dentsply Sirona Implants) in the anterior mandible. For inclusion, the implants had to be restored with prefabricated telescopic abutments (angle: 4° to 6°) and immediately loaded with an overdenture. All implants (Dentsply Sirona Implants) were placed in a subcrestal position, 2 mm below the midfacial crest and due to the implants' Morse taper connection, platform switch was applied. To eliminate micromovements and secure immobilization of the implants, they were splinted together with the relined prosthesis, which the patient was not allowed to remove during the first 10 days following surgery.

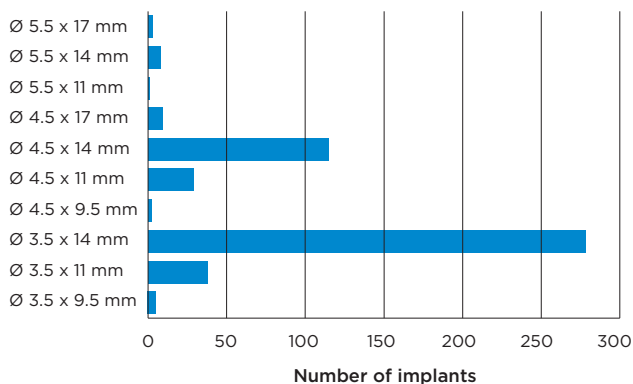


Table 1. Implant size distribution.

Following 1 year in function the implants were evaluated both radiographically and clinically. In addition, parameters such as: soft tissue health, prosthetic stability and/ or complications, bone

level remodeling, implant survival, implant success (applying criteria by Albrektsson et al.) as well as any other adverse events were registered during the investigational period.

## Results

In total, 122 patients with 488 Ankylos implants were retrospectively included in the study. The overall mean follow-up time was 79 months, ranging from 17 to 129 months.

There were 8 implants that failed to osseointegrate, rendering a cumulative survival rate of 98.4%. Applying the stricter success criteria by Albrektsson et al. where amount of bone loss is also considered, 94% of the implants were classed as successful. No prosthetic complications were reported. The periimplant soft tissues were deemed to be in excellent condition and the periimplant hard tissue showed stability with little remodeling in the majority of cases during the entire observational period where bone loss greater than 2 mm were seen only around 21 implants (4.3%).

## Discussion

Immediately loaded implant telescopic-abutment supported overdenture was shown to be a viable treatment concept for the edentulous patient. Long-term implant stability (mean follow-up of 79 months) could be shown and with the concept of a fixed detachable restoration, oral hygiene procedures, such as plaque control, were made easier which are especially advantages for the elderly patient population.

# Long-term results after subcrestal or crestal placement of delayed loaded implants

**Authors:** Romanos GE, Aydin E, Gaertner K, et al.

**Published in:** Clin Implant Dent Relat Res 2015;17(1):133-41.

## Aim

This retrospective clinical study aimed to evaluate how marginal bone maintenance is affected when Ankylos implants are placed at different depths in relation to the crestal bone.

## Material and Methods

Patient selection for this retrospective study was that patients needed to have been rehabilitated with Ankylos implants (Dentsply Sirona Implants) and restored with a fixed or removable prosthesis applying a delayed loading protocol. Mesial and distal aspects of the implant shoulder were divided into 2 groups, a subcrestal group: implant shoulders (mesial, distal or both) placed  $\geq 0.5$  mm subcrestal and a crestal group: implant shoulders placed within 0.5 mm or less from the crestal bone level. Implant shoulders placed more than 0.5 mm above the crestal bone level were excluded from the analysis.

Periotests were performed immediately after implant installation as a measure of initial implant stability. Bone level changes were analyzed from periapical radiographs.

## Results

A total of 85 patients rehabilitated with 228 delayed loaded Ankylos implants were included in the study. Mesial and distal aspects of the implant shoulders were divided into the subcrestal group,  $n=197$  and the crestal group,  $n=65$  for further analyses. The remaining 194 sites were excluded from the study since the mesial or distal side of the implant shoulder was placed more than 0.5 mm above the crestal bone level.

Periotests following implant placement measured  $-1.77 \pm 3.57$  and  $-1.77 \pm 3.26$  for the subcrestal and crestal group respectively with no statistical significant

difference. Mean follow-up time for the subcrestal group was 106 months and for crestal group 94 months. Total cumulative survival and success rates for all included implants were 97.8% and 94.7% respectively. Reason for the 5 implant failures were lack of osseointegration ( $n=1$ ) and peri-implantitis ( $n=4$ ).

For implants placed subcrestally a mean bone reduction of 1.79 mm was recorded at the last follow-up whereas implants placed in a crestal position measured a mean bone reduction of 1.38 mm. However, no statistical significant difference was shown. Mean bone level reductions at mesial and distal sites are specified in Table 1.

Group	Bone level reduction (mm)	
	Mesial site	Distal site
Subcrestal placement	1.84 $\pm$ 1.49	1.73 $\pm$ 1.31
Crestal placement	1.41 $\pm$ 1.65	1.34 $\pm$ 1.60

Table 1. Mean bone level reduction at mesial and distal sites for subcrestal and crestal placement.

## Discussion and Conclusion

This retrospective study showed that irrespective of subcrestal or crestal implant placement, Ankylos implants, when subjected to delayed loading, showed similar initial implant stability and bone remodeling with up to 8 years of follow-up.

# References

- Abboud M, Koeck B, Stark H, Wahl G, Paillon R.  
Immediate loading of single-tooth implants in the posterior region.  
Int J Oral Maxillofac Implants 2005;20(1):61-8 ..... 10
- Degidi M, Nardi D, Piattelli A.  
Prospective study with a 2-year follow-up on immediate implant loading in  
the edentulous mandible with a definitive restoration using intra-oral welding.  
Clin Oral Implants Res 2010;21(4):379-85 ..... 16
- Degidi M, Nardi D, Sighinolfi G, Piattelli A.  
Immediate rehabilitation of the edentulous mandible using Ankylos SynCone  
telescopic copings and intraoral welding: a pilot study.  
Int J Periodontics Restorative Dent 2012;32(6):e189-94 .....17
- Donovan R, Fetner A, Koutouzis T, Lundgren T.  
Crestal bone changes around implants with reduced abutment diameter placed  
non-submerged and at subcrestal positions: a 1-year radiographic evaluation.  
J Periodontol 2010;81(3):428-34 .....11
- Doring K, Eisenmann E, Stiller M.  
Functional and esthetic considerations for single-tooth Ankylos implant-crowns:  
8 years of clinical performance.  
J Oral Implantol 2004;30(3):198-209 ..... 18
- Eccellente T, Piombino M, Piattelli A, D'Alimonte E, Perrotti V, Iezzi G.  
Immediate loading of dental implants in the edentulous maxilla.  
Quintessence Int 2011;42(4):281-9 ..... 19
- Frisch E, Ziebolz D, Ratka-Kruger P, Rinke S.  
Double crown-retained maxillary overdentures: 5-year follow-up.  
Clin Implant Dent Relat Res 2015;17(1):22-31 ..... 24
- Koutouzis T, Neiva R, Nair M, Nonhoff J, Lundgren T.  
Cone beam computed tomographic evaluation of implants with platform-switched  
morse taper connection with the implant-abutment interface at different levels  
in relation to the alveolar crest.  
Int J Oral Maxillofac Implants 2014;29(5):1157-63 .....12
- Krebs M, Schmenger K, Neumann K, Weigl P, Moser W, Nentwig G-H.  
Long-term evaluation of Ankylos dental implants, part I:  
20-year life table analysis of a longitudinal study of more than 12,500 implants.  
Clin Implant Dent Relat Res 2015;17 Suppl 1:e275-86 ..... 25

Morris HF, Ochi S, Rodriguez A, Lambert PM. Aicrg, part IV: patient satisfaction reported for Ankylos implant prostheses. J Oral Implantol 2004;30(3):152-61 .....	20
Romanos GE, Aydin E, Gaertner K, Nentwig GH. Long-term results after subcrestal or crestal placement of delayed loaded implants. Clin Implant Dent Relat Res 2015;17(1):133-41 .....	27
Romanos GE, May S, May D. Implant-supporting telescopic maxillary prostheses and immediate loading. Clin Implant Dent Relat Res 2014;16(3):412-8 .....	21
Romanos GE, May S, May D. Treatment concept of the edentulous mandible with prefabricated telescopic abutments and immediate functional loading. Int J Oral Maxillofac Implants 2011;26(3):593-7 .....	26
Romanos GE, Nentwig GH. Immediate versus delayed functional loading of implants in the posterior mandible: a 2-year prospective clinical study of 12 consecutive cases. Int J Periodontics Restorative Dent 2006;26(5):459-69 .....	13



# Checklist for critical reading of clinical documentation and scientific articles

Reading scientific articles and clinical documentation is essentially about being able to judge how reliable the results are and what they mean for you in your clinical work. In order for a scientific article to be deemed credible, certain data must be present. Here is a list of important and necessary information to look for:

## **Purpose of the study**

Why was the study performed? The purpose should be compared with the conclusion.

## **Type of study**

Is it a prospective or retrospective study? Generally, prospective studies are better, since the criteria are set before the patients are treated.

## **Number of clinics involved**

How many clinics are involved? More than one clinic should be involved in the study, in order to judge the possibility of repeated results.

## **Number of patients**

How many patients are included in the study?

## **Inclusion and exclusion criteria**

What are the criteria for a patient to be included in or excluded from the study?

## **Number of implants for upper and lower jaws respectively**

The number of implants should always be listed separately for upper and lower jaws, including failure statistics, as the treatment prognosis is different in each jaw. An additional advantage is if you can see the difference between anterior and posterior treatment.

## **Follow-up**

How many implants have been followed for how long? When did the follow-up start; at installation or at loading?

## **Indications**

Which indications are covered in the study; single, partial or full bridge? If it is a full bridge, is it fixed prosthesis or overdenture?

## **Loading**

When were the implants loaded (immediate, early or conventional loading)?

## **Implants lost**

A study should include both the number of implants and number of patients not accounted for during the entire follow-up period. It should also include the reasons for drop-outs.

## **Success criteria**

What is a successful result according to the authors? It is important that the success criteria are clearly described.

## **Other important parameters**

How were the results verified? Was x-ray used when determining bone levels? How were bone levels measured? Was the bridge removed to control implant stability?

## **Statistical analysis of success and failure rates**

A study should include statistical facts and figures to reveal how many implants were actually followed up and for how long. It should also include a "worst-case" analysis, meaning a calculated failure rate assuming that all drop-outs were lost implants.

## **Complications**

If there are complications or drop-outs, they should be clearly described.

## **Conclusion**

The conclusion should be compared with the purpose of the study. Was it fulfilled? What does the study actually tell you? How does the result affect your daily clinical work?

### About Dentsply Sirona Implants

Dentsply Sirona Implants offers comprehensive solutions for all phases of implant therapy, including Ankylos®, Astra Tech Implant System® and Xive® implant lines, digital technologies, such as Atlantis® patient-specific solutions and Simplant® guided surgery, Symbios® regenerative solutions, and professional and business development programs, such as STEPPS™. Dentsply Sirona Implants creates value for dental professionals and allows for predictable and lasting implant treatment outcomes, resulting in enhanced quality of life for patients.

### About Dentsply Sirona

Dentsply Sirona is the world's largest manufacturer of professional dental products and technologies, with a 130-year history of innovation and service to the dental industry and patients worldwide. Dentsply Sirona develops, manufactures, and markets a comprehensive solutions offering including dental and oral health products as well as other consumable medical devices under a strong portfolio of world class brands. As The Dental Solutions Company™, Dentsply Sirona's products provide innovative, high-quality and effective solutions to advance patient care and deliver better, safer and faster dentistry. Dentsply Sirona's global headquarters is located in York, Pennsylvania, and the international headquarters is based in Salzburg, Austria. The company's shares are listed in the United States on NASDAQ under the symbol XRAY.

Visit [www.dentsplysirona.com](http://www.dentsplysirona.com) for more information about Dentsply Sirona and its products.